

Histopathological findings in lung biopsies with usual interstitial pneumonia: Definition of a new classification score for histological fibrotic stages

Mária Makovická^{1,2}, Adela Vrbenská³, Peter Makovický^{1,4}, Barbora Durcová⁵, Jozef Škarda⁶, Vojtěch Kamarád¹, Mária Miklošová⁷, Kvetoslava Rimárová⁸, Patricie Michalčová¹, Klaudia Kráľová^{2,9} and Jozef Muri¹

¹ Department of Histology and Embryology, Faculty of Medicine, University of Ostrava, Czech Republic

² Cancer Research Institute, Biomedical Research Centre of the Slovak Academy of Sciences, Bratislava, Slovakia

³ Department of Pathology, National Institute for Tuberculosis, Lung Diseases and Thoracic Surgery in Vyšné Hágy, Slovakia

⁴ Infectious Diseases and Preventive Medicine, Veterinary Research Institute, Brno, Czech Republic

⁵ Department of Pneumology and Phtisiology, National Institute for Tuberculosis, Lung Diseases and Thoracic Surgery in Vyšné Hágy, Slovakia

⁶ Institute of Molecular and Clinical Pathology and Medical Genetics, Faculty of Medicine, University of Ostrava, Czech Republic

⁷ Department of Anatomy, Faculty of Medicine, University of Ostrava, Czech Republic

⁸ Department of Public Health and Hygiene, Faculty of Medicine, Pavol Jozef Šafárik University in Košice, Slovakia

⁹ Department of Zoology, Faculty of Natural Sciences, Comenius University, Bratislava, Slovakia

Abstract. The objective of this article is to describe and classify usual interstitial pneumonia (UIP) changes according to their relevance in the pathology of the idiopathic pulmonary fibrosis (IPF) process. In a cohort of 50 patients (25♀, 25♂) with UIP findings, the percentage ratio between fibrotic and preserved parts of the lungs was quantified. Three quantitative stages of fibrotic involvement of the lung parenchyma and concomitant changes were defined. These are initial ($\leq 20\%$), advanced (21–40%), and diffuse ($\geq 41\%$) fibrosis of the lungs. Histologically, temporal heterogeneity is predominant with thickened alveolar septa, interstitial fibrosis, and the presence of fibroblastic foci up to mature diffuse fibrosis with honeycomb changes. The finding is accompanied by variably mature lymphocytic inflammation, presence of macrophages, emphysema, bronchioloectasia of the alveoli, bronchiectasis, bronchial muscle wall hypertrophy, hypertrophy of the vessel walls, alveolar mucosa, focal haemorrhage, and hyalinization of the lungs. Pneumocyte hyperplasia, occasionally atypical in appearance with hobnail changes, as well as squamous metaplasia are observed. In the methodically quantified stages of fibrous involvement, 14 subjects were classified (6♀, 8♂) into the stage of initial fibrosis, 21 subjects (11♀; 10♂) into the stage of advanced fibrosis, and 15 subjects (8♀; 7♂) into the stage of diffuse fibrosis.

Key words: Lung biopsy — Lung fibrosis — Idiopathic interstitial pneumonia — Pneumopathology — UIP

Correspondence to: Jozef Muri, Department of Histology and Embryology, Faculty of Medicine, University of Ostrava, Ostrava, Czech Republic

E-mail: muri.jozef@gmail.com

Kvetoslava Rimárová, Department of Public Health and Hygiene, Faculty of Medicine, Pavol Jozef Šafárik University, Košice, Slovakia

E-mail: kvetoslava.rimarova@upjs.sk

© The Authors 2024. This is an **open access** article under the terms of the Creative Commons Attribution-NonCommercial 4.0 International License (<https://creativecommons.org/licenses/by-nc/4.0/>), which permits non-commercial use, distribution, and reproduction in any medium, provided the original work is properly cited.

Introduction

In the 1980s, when coal mining in Czechoslovakia was gradually eliminated, the major mines were definitively closed and currently only some of them are working. In a relatively short period of time, these events were reflected in the realm of specialized medical practices, particularly in the field of pneumology. By that time, the prevailing pulmonary diseases of silicosis and miners' pneumoconiosis had been replaced by lung tumours, respiratory infections, civilization diseases and congenital developmental lung diseases. This was also reflected in the practices of other medical disciplines such as post-acute and spa medicine, which were compelled to adapt to these circumstances. Perhaps this is the reason why oncologic issues, inflammatory fibroproductive pulmonary processes, and infectious pneumonias dominate pneumopathology today (Wang et al. 2021; Holubova et al. 2022; Podolanczuk et al. 2023). Some of the interstitial inflammatory processes of the lungs remain of unclear origin and are associated with progressive fibrosis of the lung parenchyma with gradual shrinkage of the alveolar spaces. There is also a significant increase in fibrous tissue, leading to thickening and fusion of the alveolar septa with a consequent reduction in the vital capacity of the lungs. These changes are accompanied by secondary cardiac damage and associated cardiovascular pathology. Although interstitial pneumonias have undergone several classification changes over the past few decades, a number of these diseases are difficult to classify (Wijsenbeek et al. 2022; Hosseini and Salvatore 2023). These include also idiopathic pulmonary fibrosis (IPF), which is associated with the histological findings of usual interstitial pneumonia (UIP). The latter is microscopically characterized by loss of alveolar architectonics, remodeling of lung tissue, presence of fibroblast foci, and a final honeycombing. Although epidemiological data are partially divergent, it is assumed that the worldwide prevalence is 13-20/100,000 and the incidence is in the range of 6.8–16.3/100,000 individuals (Vasakova 2017). From our setting, we report the results of a paper which suggests that the prevalence in the Moravian-Silesian Region in 1981-1990 was 6.5–12.1/100 000 individuals and the incidence fluctuated at 0.74–1.28/100 000 individuals (Muri et al. 2022). Nowadays, despite the continuous improvement of diagnostic procedures, the

improvement of instrumentation and the introduction of more sensitive laboratory parameters, IPF is often not verified in practice until an advanced stage. At present, we can define the main challenges of addressing and approaching the early diagnosis of IPF in several points. The introduction of new, more sensitive markers that can detect predisposition to disease or signal the onset of the disease at an early stage is needed. The identification of risk factors involved in the initiation and progression of the disease itself as well as the development of new therapeutic approaches are important. Studies based on the identification and description of individual changes in the lung parenchyma during the development of UIP might be helpful in addressing the above challenges. The identification of correlations between pathological changes in the lungs and their causal temporal consistency is crucial. The objective of this article is to describe and classify changes in the lung parenchyma according to their relevance in the pathology of the IPF process based on a representative cohort of patients with histological findings of UIP.

Material and Methods

Samples and material processing

The material was obtained by video-thoroscopic lung biopsy from patients who were hospitalized with unspecified interstitial lung disease in the National Institute for Tuberculosis, Lung Diseases and Thoracic Surgery in Vyšné Hágy, Slovakia (NITLDT'S). The cohort consisted of 50 patients (25♀ and 25♂). Basic data on the patients are presented in Table 1. The collected specimens were delivered to the Pathology Department and were processed by a standard histological technique down to paraffin blocks. Subsequently, they were sliced on a microtome and stained with Hematoxylin-eosin staining (Bamed, s.r.o., Czech Republic) and with Masson's trichrome (Bamed, s.r.o., Czech Republic) for evidence of fibrosis. The prepared slides were examined under a light microscope BX53 (Olympus, Japan). Using the ZEN program (Zeiss, Germany), the percentage ratio between fibrotic and preserved part of the lungs was quantified in each slide. The possibility of using the samples for research purposes was approved by the ethics committee of the NITLDT'S (1/2022 Ek NITLDT'S).

Results

Histological findings

The specimens are dominated by remodeling of the lung parenchyma with fibroblastic foci, exhibiting variable degrees

Table 1. Basic patient data

	<i>n</i>	Age		
		average	min	max
Women	25	65	49	75
Men	25	62	32	77

n, number of patients.

Table 2. Changes and relationships between individual findings

Changes in the affected and preserved parts of the lungs				
Descriptive appearance	Percentage appearance	Histological appearance	Inflammation	Histological finding
Initial	≤20%	Fibrosis of the alveolar septa	Lymphocytic inflammation Individual macrophages	Emphysema Bronchioloectasia of the alveoli Bronchioectasia
Advanced	21–40%	Fibroblastic proliferation Confluent fibrotic areas More or less expressed fibroblast foci	Lymphocytic inflammation Focal macrophage multiplication	Hypertrophy of the bronchial wall Hypertrophy of the vessel wall
Diffuse	≥41%	Fusing and diffuse fibrosis	Lymphocytic inflammation Individual lymphocytic follicles Focal multiplied macrophages Polymorphonuclears Purulent inflammatory exudate	Mucostasis of the alveoli Focal haemorrhage Hyalinization of the lungs Hyperplasia of pneumocytes Atypical pneumocytes Squamous metaplasia of pneumocytes

of fibrosis with areas of initial, advanced, confluent, and diffuse fibrosis and accompanying lymphocytic inflammation, individual or focally multiplied macrophages, and a focal purulent exudate. In the lung tissue, there are ruptured alveolar septa, bronchioloectasia of alveoli, bronchiectasis with peripheral smooth muscle hypertrophy, smooth muscle hypertrophy of blood vessels, and focal intimal proliferation of small vessels. Pneumocytes with hobnail changes, including the presence of atypical pneumocytes with hyperplasia and focal squamous metaplasia of pneumocytes. Mucostasis in the alveoli, focal haemorrhage and hyalinization of the alveolar spaces are present in some places as well focal oedematous and fibrotic pleura.

Morphometry

Three groups of pulmonary fibrosis were defined and assigned a classification score in the form of descriptive and diffuse appearance. Changes in the affected and preserved parts of the lungs were added to these groups (Table 2). The results are presented in Table 3. The results show that in each methodologically quantified stage, 14 subjects (6♀, 8♂) were classified with initial, 21 subjects (11♀; 10♂) with advanced and 15 subjects (8♀; 7♂) with diffuse fibrosis, respectively. In the quantified mean percentage appearance, the extent of fibrosis was 35% of the total lung area (36.8♀; 33.2♂).

Discussion

Pneumopathology is developing very dynamically in the context of increasing incidence of lung diseases worldwide. This also applies to progressive idiopathic interstitial

pneumonias (IIP). IPF is classified as IIP (Maxwell 2022). It is a specific form of adult chronic fibrotic interstitial lung disease of unclear aetiology with pneumocyte damage and fibroblast dysregulation. Disease progression is defined by a combination of clinical, functional, and radiological parameters, as well as the histological pattern. IPF is directly related to UIP, and it is recognized that not every UIP finding corresponds to IPF. The term UIP was first used in 1969 as part of a classification scheme for interstitial pneumonias (Liebow and Carrington 1969). The definition at that time was based on a pattern of interstitial proliferation excluding other subtypes of interstitial pneumonias with the presence of hyalinised membranes, exudate, and diffuse alveolar damage. Later, the presence of fibroblastic foci was added to the typical pattern (Myers and Katzenstein 1998), and the finding of UIP became part of chronic fibrotic interstitial lung diseases with a causal relationship to IPF (Katzenstein and Myers 1998). The 2011 guidelines brought changes in diagnosis that also affected pulmonary pathologists. Based on high-resolution CT (HRCT), bronchoalveolar lavage (BAL), surgical lung biopsy, transbronchial lung biopsy or cryobiopsy may or may not be recommended (Raghu et al. 2018). In cases of HRCT of indeterminate pattern, histo-

Table 3. Results of morphometry

	Fibrosis of the lungs			
	Appearance (n)			Appearance (%)
	Initial	Advanced	Diffuse	
Women	6	11	8	36.8
Men	8	10	7	33.2
Total	14	21	15	35

n, number of patients.

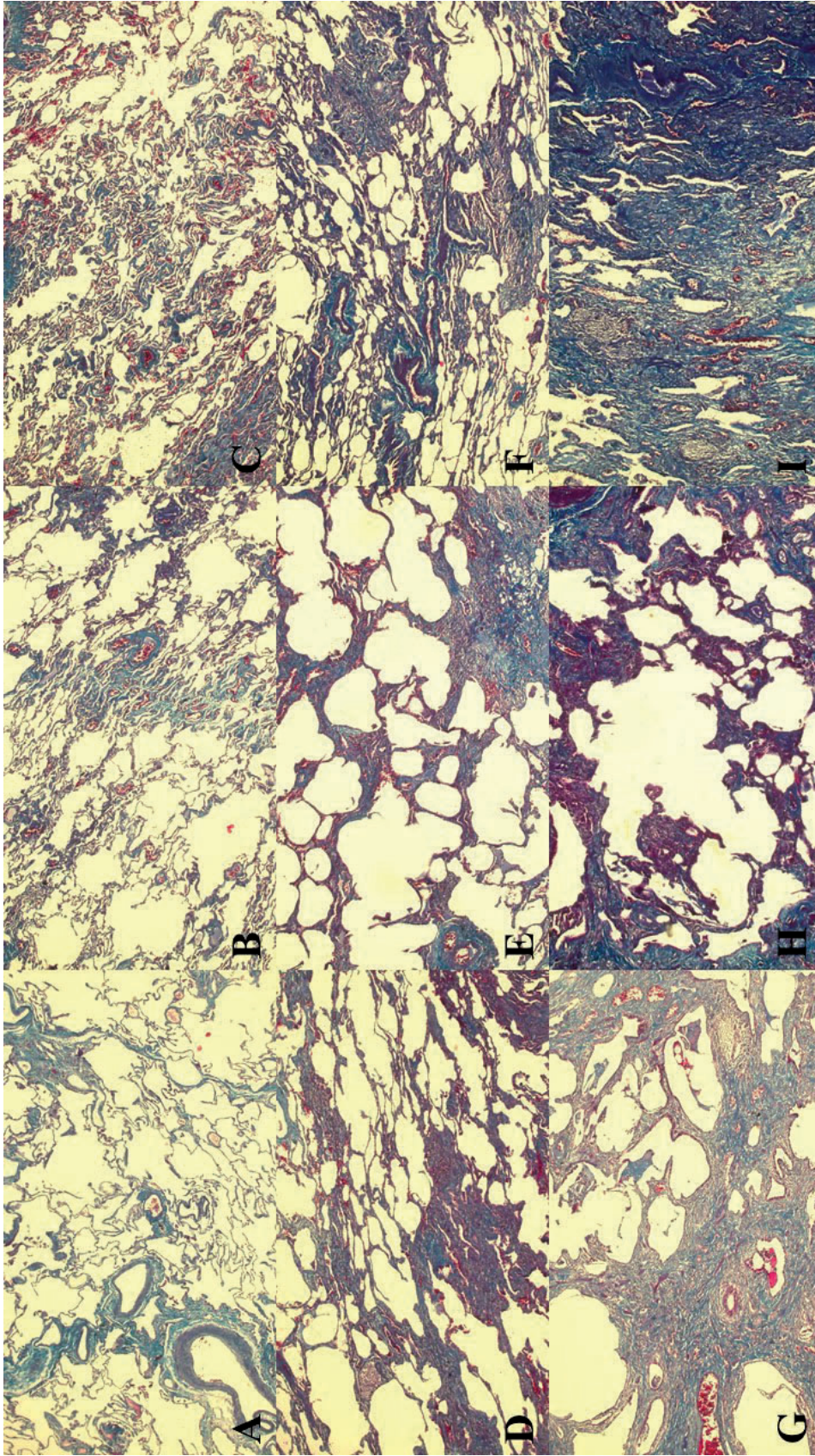


Figure 1. Practically into the full material there are thickened alveolar septa with cell proliferation and production of fibrous fibres that mature into collagen. The process sometimes appears to be in relation with larger vessels (A) with perivascular sinusoidal distribution to adjacent parts (B) with the formation of variably thicker fibrous parts (C). Subsequently, fibroblast foci form (D), and the full findings are characterized with progressively fibrosis (E). Part of the airspace of the lungs remains compressed (F), but part of the alveoli rupture (G), including the formation of air bullae that are bordered by masses of mature collagen (H) or the entire area remains affected by fibrosis (I). Masson trichrome: 50x.

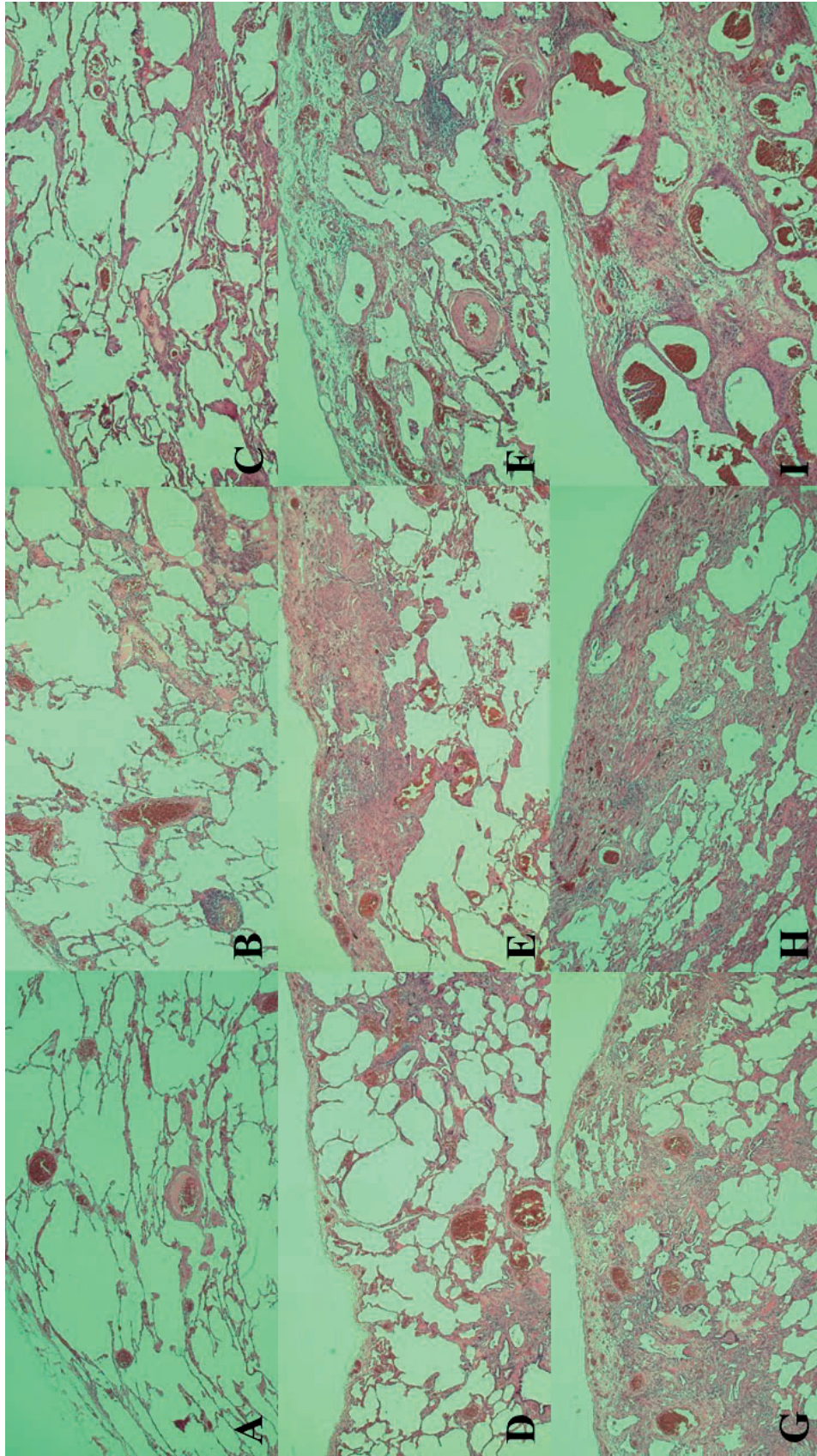


Figure 2. Lung parenchymal remodeling proceeds from multiple directions, with peribronchovascular predominance in the early stage (A). Subsequently thicker fibrous plaques form (B) subpleurally and especially in the central parts of the specimens (C). In advanced stages of fibrosis, fibroblast foci are visible (D). Elsewhere, the relationship is seen with the pleura (E) being edematous (F) fibrotic (G) with increasing area of fibrosis (H) and in cases of diffuse fibrosis underlying the edematous stroma, there are masses of mature collagen with the presence of a dispersed lymphocytic inflammation and ruptured variably sized alveoli with erythrocytes in the lumen (I). H&E; 50x.

logical examination may provide evidence of other types of lung disease. Thus, it is always advisable that several biopsy specimens or a larger surgical resection extending beyond the zone of florid fibrosis should be submitted for histological examination. However, this is not always possible in individuals with reduced vital capacity of the lungs and in patients where the utility of sampling from multiple areas is questionable. In the material we have examined, it appears that some types of UIP may also be more aggressive, which could be related to genetic predisposition. Regarding this, we have already published papers that point to the importance of recognizing previously undescribed types of mutations that could function as triggers for diseases (Makovicky 2015; Rimarova et al. 2022). Several papers have already confirmed the existence of relationships between genetic predisposition and the development of fibrosis (Tirelli et al. 2022). Perhaps part of IPF research might go in a similar direction. In fact, it seems that the aetiology of the disease could correspond to the histological patterns of fibrosis. Our observations suggest that UIP is characterized by architectural changes in the lungs parenchyma, fibrosis, and concomitant histological changes. We classified the concomitant histological changes based on their presence in the affected and preserved parts of the lungs. Fibrosis remains the predominant finding, which is regularly reported in other literature references (Visscher and Myers 2006). Based on the pathophysiology of IPF, the agent is thought to initiate type I pneumocyte damage or even endothelial damage with a subsequent response in the form of fibroblast activation (White et al. 2003). Thus, it is questionable whether the presence of inflammation is one of the primary causes of UIP progression or whether it is merely a secondary response of the immune system to lung injury. Some papers have failed to demonstrate a causal relationship between the presence of inflammation and UIP because fibrosis developed in experimental material even in the absence of inflammation (Selman et al. 2001). On the other hand, if we assume that the presence of macrophages may play a negative role in relation to fibroblast proliferation, then inflammation may represent a potentially important change in the development of UIP. We have classified fibrosis into three separate groups corresponding to its extent. It can be concluded that the entire process is highly dynamic with variable progression and distribution, which we have to describe (Figure 1A–I). In addition, we have tabulated the attributes of inflammation. These causalities can be useful in recognizing the stage of the disease and as prognostic indicators of IPF. It is assumed that the finding of UIP starts in several places into the centre of the lungs with extension to the periphery of the lungs. Unshaped fibrosis and/or thickened fibrotic portions in the subpleural and paraseptal regions have been observed (Klingerman et al. 2009; Wuyts et al. 2014). This corresponds with our observations of focal oedematous pleurae with subpleural foci of prominent

interstitial fibrosis, occasional foci of hyalinization with the presence of lymphocytic inflammation as well as areas of dense fibrosis with mature collagen fibres. In the microscopic image, less or more prominent fibrotic parts alternate with partially preserved sections of the lungs, and fibroblast proliferation are initiated from multiple locations simultaneously (Figure 2A–I). In some cases, the fibrosis is in contact with the periphery of the blood vessels and extends into the adjacent alveolar septa. These frequently rupture and there is a proliferation of fibrous tissue in their vicinity with an accompanying inflammatory reaction. However, this is not a homogeneous pattern as in other parts the alveolar septa are thickened by fibrosis or there is alveolar compression even with the presence of macrophages in the lumen. In doing so, fibroblast foci are formed. In advanced stage mass of fibrotic tissue with some compressed, or ruptured alveoli are visible. Such findings were present in diffuse fibrosis samples. However, these may no longer be diagnostically relevant because the microscopic image is dominated by massive fibrosis. Areas of adequately aerated, partially aerated, and non-aerated lungs alternate in the specimens with the presence of chronic alveolar emphysema with peripheral thickened alveolar septa and varying percentages of honeycomb changes. A part of the bronchi is dilated with hypertrophy of the adjacent smooth muscle. There is compensatory hyperplasia of pneumocytes in the alveolar septa and the presence of atypical pneumocytes with squamous metaplasia of pneumocytes. These changes are pathognomonic at first, documenting the persistent activity of the process. Concomitant changes include variably developed lymphocytic inflammation, macrophages, purulent inflammatory exudate, and focal haemorrhage. Similar changes have been described in several UIP specimens and are comparable to our findings (Figure 3A–I). As part of the comparison of diagnostic and morphometric findings, it would be useful to compare our quantified fibrosis stages with the clinical findings, including findings of the percentage area of fibrosis of the lungs with the quantified areas from other imaging techniques based on magnetic resonance imaging. Any differences could be useful in deciding the location of sampling for histopathological examination.

Conclusion

In the cohort of diagnosed IPF patients, whose videothoroscopically collected lung samples were sent for histopathological examination, well-developed UIP criteria with the presence of main and concomitant changes are evident. Fibrosis predominates in the findings. Correlations between the percentage extent of fibrosis, inflammation and other concomitant changes are also suggested. The identification of individual changes and the relationships

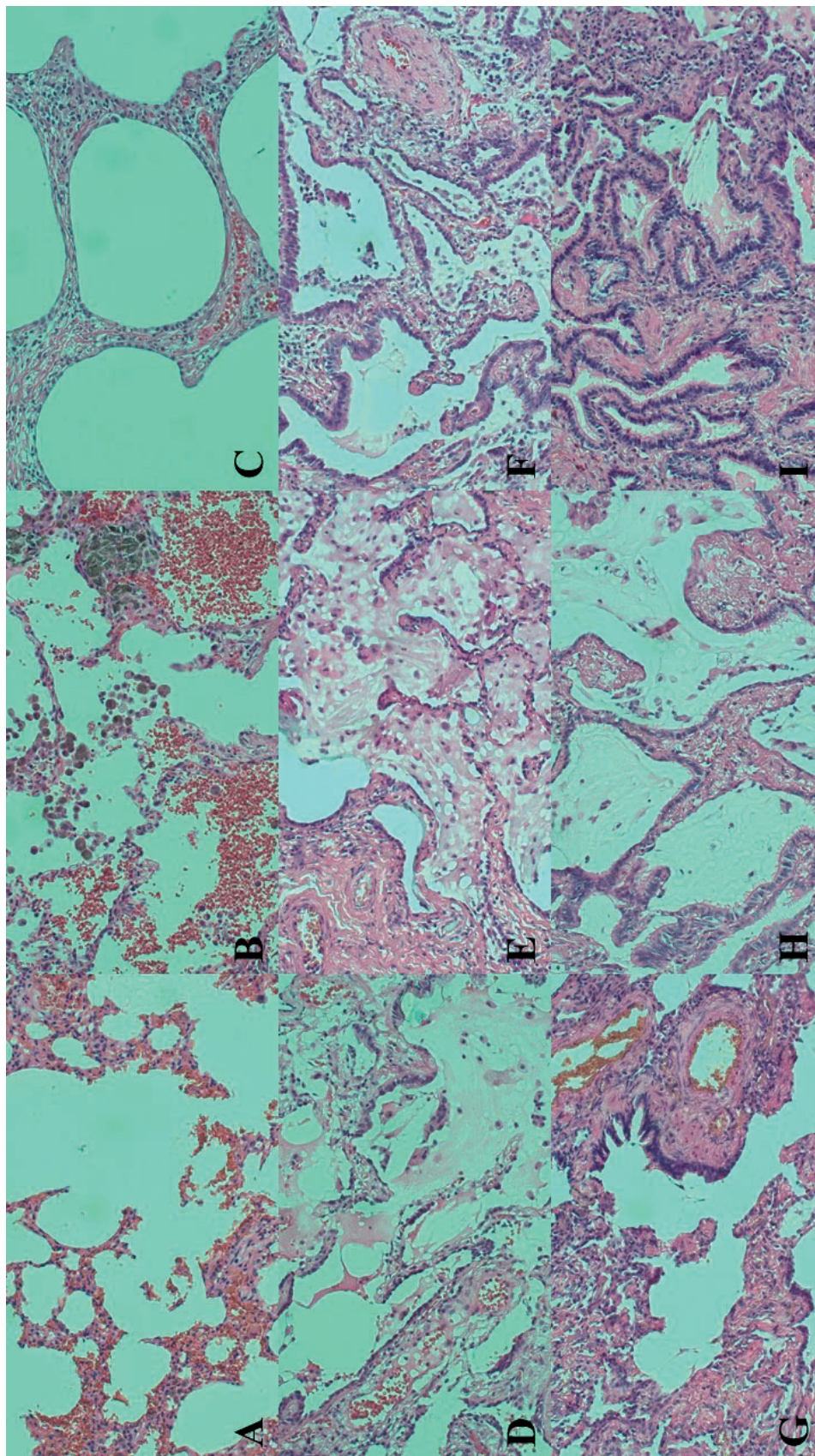


Figure 3. Concomitant changes with the finding of ruptured blood-stained alveolar septa (A) with the presence of histiocyte clusters (B). A view of thickened fibrous alveolar septa, mature collagen and presence of sparse lymphocytic inflammation (C). Shapeless thickened fibrous alveolar septa with mucostasis and mildly regressed altered pneumocytes (D). Thickened predominantly ruptured fibrous alveolar septa with hypertrophic pneumocytes and mucostasis (E). Shapeless thickened fibrous alveolar septa with hypertrophic pneumocytes, mucostasis and concomitant lymphocytic inflammation (F). Underlying fibrosis of ruptured alveolar septa with bronchioloectasia (G). A view of the thickened fibrous alveoli with a rim of cylindrical epithelium with cilia (H). Clusters of compressed alveoli with bronchioloectasia and concomitant lymphocytic inflammation in the area of fibrosis (I). H&E; 200x.

between them are partly dependent on the sampling location, the number of samples taken as well as the stage of differentiation of fibrosis and the stage of progression of the disease itself.

Conflict of interest. The authors have no conflicts of interest to report.

Acknowledgement. Supported by KEGA 008UPJŠ-4/2020, KEGA 010UPJŠ-4/2021, MZE-RO0523. Special thanks to Dr. Ludmila Faldíková for her English editorial assistance with this manuscript.

References

- Holubova J, Stanek O, Juhasz A, Soumana IH, Makovicky P, Sebo P (2022): The Fim and FhaB adhesins play a crucial role in nasal cavity infection and Bordetella pertussis transmission in a novel mouse catarrhal infection model. *Plos Pathogens* **18**, 1-33
<https://doi.org/10.1371/journal.ppat.1010402>
- Hosseini M, Salvatore M (2023): Is pulmonary fibrosis a precancerous disease? *Eur. J. Radiol.* **160**, 110723
<https://doi.org/10.1016/j.ejrad.2023.110723>
- Katzenstein AL, Myers JL (1998): Idiopathic pulmonary fibrosis: clinical relevance of pathologic classification. *Am. J. Respir. Crit. Care Med.* **157**, 1301-1315
<https://doi.org/10.1164/ajrccm.157.4.9707039>
- Kligerman SJ, Groshong S, Brown KK, Lynch DA (2009): Nonspecific interstitial pneumonia: radiologic, clinical, and pathologic considerations. *Radiographics* **29**, 73-87
<https://doi.org/10.1148/rg.291085096>
- Liebow A, Carrington CB (1969): The interstitial pneumonias. In: *Frontiers of Pulmonary Radiology*. (Eds. Simon M, Potchen EJ, LeMay M) pp. 102-141. Grune & Stratton, New York
- Makovicky P (2015): What does modern veterinary pathology have to offer? *ARC J. Anim. Vet. Sci.* **1**, 43-47
- Maxwell LS (2022): The histologic diagnosis of usual interstitial pneumonia of idiopathic pulmonary fibrosis. Where we are and where we need to go. *Mod. Pathol.* **35**, 8-14
<https://doi.org/10.1038/s41379-021-00889-5>
- Muri J, Chylikova J, Skarda J, Miklosova M, Kamarad V (2022): The role of tumor-associated macrophages in solid malignancies – an overview of current knowledge. *Biomed. Pap. Fac. Palacky Olomouc Czech Repub.* **166**, 136-139
<https://doi.org/10.5507/bp.2021.070>
- Myers JL, Katzenstein AL (1998): Epithelial necrosis and alveolar collapse in the pathogenesis of usual interstitial pneumonia. *Chest* **94**, 1309-1311
<https://doi.org/10.1378/chest.94.6.1309>
- Podolanczuk AJ Thomson CC, Remy-Jardin M, Richeldi L, Martinez FJ, Kolb M, Raghu G (2023): Idiopathic pulmonary fibrosis: state of the art for 2023. *Eur. Respir. J.* **61**, 2200957
<https://doi.org/10.1183/13993003.00957-2022>
- Raghu G, Remy-Jardin M, Myers JL, Richeldi L, Ryerson CJ, Lederer DJ, Behr J, Cottin V, Danoff SK, Morell F, et al. (2018): Diagnosis of idiopathic pulmonary fibrosis. An Official ATS/ERS/JRS/ALAT Clinical Practice Guideline. *Am. J. Respir. Crit. Care Med.* **198**, 44-68
<https://doi.org/10.1164/rccm.201807-1255ST>
- Rimarova K, Samasca G, Makovicky P, Zakova P, Lupan I, Dorko E, Diabelkova J, Kanukova L, Jenca A, Patrasova A, et al. (2022): Genetically modified rodent models and celiac, non-celiac gluten sensitivity: a minireview. *Cent. Eur. J. Public Health* **30**, S27-S31
<https://doi.org/10.21101/cejph.a6810>
- Selman M, King TE, Pardo A (2001): Idiopathic pulmonary fibrosis: prevailing an evolving hypotheses about its pathogenesis and implications for therapy. *Ann. Intern. Med.* **134**, 136-151
<https://doi.org/10.7326/0003-4819-134-2-200101160-00015>
- Tirelli C, Pesenti C, Miozzo M, Mondoni M, Fontana L, Centanni S (2022): The genetic and epigenetic footprint in idiopathic pulmonary fibrosis and familiar pulmonary fibrosis: A state-of-the-art review. *Diagnostics (Basel)* **12**, 3107
<https://doi.org/10.3390/diagnostics12123107>
- Vasakova M (2017): Idiopathic pulmonary fibrosis. Can we always diagnose and treat it right? *Vnitr. Lek.* **63**, 796-801 (in Czech)
<https://doi.org/10.36290/vnl.2017.151>
- Visscher DW, Myers JL (2006): Histologic spectrum of idiopathic interstitial pneumonias. *Proc. Am. Thorac. Soc.* **4**, 322-329
<https://doi.org/10.1513/pats.200602-019TK>
- Wang Q, Zhang X, Chen D (2021): circ_VMA21 protects WI-38 cells against LPS-induced apoptotic and inflammatory injury by acting on the miR-409-3p/KLF4 axis. *Gen. Physiol. Biophys.* **40**, 275-287
https://doi.org/10.4149/gpb_2021011
- White ES, Lazar MH, Thannickal VJ (2003): Pathogenetic mechanism in usual interstitial pneumonia/idiopathic pulmonary fibrosis. *J. Pathol.* **201**, 343-354
<https://doi.org/10.1002/path.1446>
- Wijsenbeek M, Suzuki A, Maher TM (2022): Interstitial lung diseases. *Lancet* **400**, 10354
[https://doi.org/10.1016/S0140-6736\(22\)01052-2](https://doi.org/10.1016/S0140-6736(22)01052-2)
- Wuyts WA, Cavazza A, Rossi G, Bonella F, Sverzellati N, Spagnolo P (2014): Differential diagnosis of usual interstitial pneumonia: when is it truly idiopathic? *Eur. Respir. Rev.* **23**, 308-319
<https://doi.org/10.1183/09059180.00004914>

Received: June 14, 2023

Final version accepted: September 6, 2023